

Diagnostic and Treatment of Ovarian Cystic Lesions in Premenarcheal Girls: a 3 Year Study

IOANA ANCA STEFANOPOL^{1,2}, ZINA TIRON¹, ANCA IULIA NEAGU^{1,2*}, LILIANA LACRAMIOARA PAVEL^{1*}, VASILE SARBU³, EMILIANA TEODORA DRAGOMIR-ANANIE²

¹Dunarea de Jos University of Galati, Faculty of Medicine and Pharmacy, Morphological and Functional Sciences Department, 47 Domneasca Str, 800008, Galati, Romania

²Sf. Ioan Clinical Emergency Hospital for Children, 2 Gh. Asachi Str., 800487, Galati, Romania

³Ovidius University, Department of Surgery, Campus, 1 Universitatii Alley, 900470, Constanta, Romania

Ovarian cystic lesions, once considered uncommon in children, represent nowadays subject for many studies. Controversies regarding the diagnostic and treatment still exist. Unspecific symptoms and difficulties in performing an accurate ultrasound in children, sometimes led to misdiagnose this condition. Ovarian cystic lesions in premenarcheal girls may have hormonal influence, changing the biochemical balance, so an endocrinologist should be consulted. The main goal is to preserve the adnexal tissue. The purpose of this study is to analyze the diagnostic and treatment of ovarian cystic lesions in premenarcheal girls, highlighting the opportunity of a multidisciplinary team and the necessity of the ovarian preservation.

Keywords:premenarcheal, ovarian cyst, hormones, cystectomy

In the past, finding an ovarian cystic lesion (OCL) in a premenarcheal girl, was considered a good reason of concern. This fact justified a too aggressive treatment, consisting in laparotomy and even oophorectomy. The higher rate of ovarian cysts visualisation on abdominal ultrasound and their benign nature on histological examinations, suggest that this pathology is more common then previously thought, and consequently, pediatric surgeons had to reevaluate the management in order to preserve as much ovarian tissue as possible for a proper fertility.

Ovaries are never quiescent; they suffer structural changes due to biochemical influence of pituitary hormones. A good knowledge of chemistry and biochemistry of the hormonal balance, is important in understanding the physiopathology of OCL.

Ovarian lesions in children are histopathologically classified in non-neoplastic or functional cysts, and neoplastic (benign or malignant)[1, 2]. Functional cysts, like follicular cysts or corpus luteal cysts, represent the most frequent ovarian lesions, while the most common benign neoplasms are cystic mature teratomas and serous cyst adenomas[3,4]. Only 10% of the ovarian lesions are malignant, with two-third being germ cell tumors [5] and according to Brookfield et al [6], the incidence of malignant ovarian neoplasms in patients under 9 years of age, was 0.102: 100,000 girls per year. Etiology, symptoms, ultrasonographical aspect and management of ovarian cystic lesions (OCL) in pediatric patients are different, based on pubertal status and age. The moment when the ovarian morpho-physiology changes is the menarche. Regardless of age, the ovaries have follicles, but their number and size depend on the chemical influence of gonadotropins levels [7]. In premenarcheal girls, the ovaries have usually homogeneous echotexture[8], but frequently can be seen multiple small cystic lesions (<9mm), representing follicles. Some of them will grow over 10 mm, becoming ovarian cysts which usually regress spontaneously; this happens in perimenarcheal period [9].

There are no specific clinical manifestations for an uncomplicated OCL. Even when complicates, usually by torsion or rupture, it can be easily misdiagnosed as other more frequent cause of acute abdomen, such as acute appendicitis [4]. Although quite rare, may occur signs of precocious puberty, due to estrogen production from a functional cyst [10].

Imaging investigation are indispensable for diagnosis and surveillance. Abdomino-pelvic ultrasound (US) may be sufficient, but sometimes, setting an accurate diagnosis may require computed tomography (CT) or magnetic resonance imaging (MRI)[11]. In the presence of a complex or voluminous OCL, susceptible to malignancy, tumoral markers may be helpful[12].

OCL treatment became less aggressive, in order to spare ovarian tissue. It mainly consists of US follow-up, or of ovary-preserving operating techniques even in case of torsion [13].

* email: ancazanoschi@gmail.com, doctorpavel2012@yahoo.com

In this study we analyzed the diagnostic and treatment of ovarian cystic lesions in premenarcheal girls within a 3 years period. These informations may help improve the OCL management in premenarcheal girls, highlighting the opportunity of a multidisciplinary team and the necessity of the ovarian preservation.

Experimental part

Our study includes 3296 patients aged 0-18 years, presented at the Clinical Emergency Hospital for Children “Sfântul Ioan”, Galați, between January 2017 and December 2019; 3267 (99%) were patients with abdomino-pelvic US, and 31 patients (1%) had OCL discovered incidentally at the time of abdomino-pelvic surgery. We excluded the patients with unknown menarche age or incomplete informations (76), malignancies (1), paraovarian cysts (8) and documented polycystic ovary syndrome (3). Finally, were enrolled 3208 patients, of whom 488 (15.2%) were found to have OCL ≥ 10 mm.

We collected data from electronic and paper hospital records. We obtained the ethical approval for the publication of the study, from our institution (“Sf. Ioan” Children’s Emergency Hospital, Galați, Romania).

We analyzed the age at presentation, symptoms, cysts size and aspect on ultrasound, MRI/CT scans and tumor markers for selected cases, treatment, anatomo-pathological findings for operated cases, and follow up for all the 488 patients who were found to have OCL ≥ 10 mm either on abdominal sonographic examination (457; 93.6%) or incidentally at the time of abdomino-pelvic surgery (31; 6.4%). We discovered 52 (10.65%) premenarcheal girls, diagnosed on US (46; 84.5%) or intraoperatory (6; 15.5%).

On US, the cyst size was considered to be the largest measurement in any of the 3 dimensions (length, width, depth), and we formed 3 groups: 10-29 mm (small), 30-49 mm (medium) and ≥ 50 mm (large). Cysts smaller than 10 mm weren’t included, being considered as physiological ovarian follicles. Regarding US features, we classified ovarian cysts in simple and complex. We defined as simple a cyst unilocular, with an echoic fluid, well-defined by a thin wall, without septations or solid components, and as complex a cyst multilocular, with solid areas and which may have septations, or echogenic wall, or internal echoes [9, 14].

The most common clinical manifestations were: abdominal pain (42 cases), headaches (6), nausea (13), vomiting (8), dysuria (4) and palpable tumor (5). We also encountered vaginal bleeding (1), acne (4) and moderate hirsutism (2). 11 patients (21%) were asymptomatic or without abdominal symptoms, being discovered on a routine ultrasound.

The management was conservative or surgical. We consider the treatment to be conservative, when it does not involves any surgical action, therefore it only consists in ultrasonographic survey. Patients were asked to return for US control at one month; if the cyst persisted, we performed US until the complete resolution or surgery. In order to evaluate the recurrence risk, patients were asked to return for US control over 1 year. Regarding the surgical treatment, operations were performed either emergently (within the first 24 hours after the presentation), or as elective surgery. Operating procedures were conservative (cystectomy) or radical (salpingo-oophorectomy)

Results and discussions

Etiology, symptoms, ultrasonographic aspect and management of ovarian cystic lesions (OCL) in pediatric patients are different, based on pubertal status and age.

In utero, the fetal ovary is under the influence of maternal estrogen, fetal gonadotropins, and placental HCG; this explains the development of the follicular cysts, which can be found on ultrasound starting from week 28 of gestation [15]. In prepubertal patients, ovarian cysts should be less common because of the low levels of estradiol and gonadotropin. However, during childhood, ovaries are not dormant, maturation and involution of follicles occurring at a low rate, because of intermittent discharge of gonadotropins [16-19]; this may be the cause for some OCL found in this group age. Once the menarche occurs, ovarian cysts incidence increases [9], the main physiopathological mechanism for their occurrence being ovulation failure; from this moment, ovary will suffer monthly structural changes consisting of the follicular growth and involution.

In premenarchal girls, small cystic lesions under 9 mm, representing follicles, may be seen. Although in 2010 at the Society of Radiologists in Ultrasound Consensus Conference, it was stated to consider as ovarian cysts only lesions measuring more than 30 mm [22], and although other previous authors chose the largest diameter for a normal follicle to be 20 mm, we decided to use as a cut-off limit the size of 10 mm to see if in our premenarcheal patients, small cysts have clinical echo. In support of our theory comes the study of King et al. [21, 23] that found ovarian cysts larger than 9 mm to be an indicator of ovarian activation in prepubertal ages. In our study were enrolled 488 patients who were found to have OCL ≥ 10 mm either on abdominal sonographic examination (457; 93.6%) or incidentally at the time of abdomino-pelvic surgery (31; 6.4%). We discovered 52 (10.65%) premenarcheal girls, diagnosed on US (46; 84.5%) or intraoperatory (6; 15.5%). Patients ranged in age from 2 to 15 years, with 10.1 years being the average. There are few studies where patients

were divided according to menarche occurrence. Kaniszai et al. found only 5 (4.2%) premenarcheal patients of a total 119 girls with hormonal treatment, aged from 5 to 18 years, [25], while Bergeron et al., in a group of 191 operated patients found an incidence of 26% [26].

There were 46 premenarcheal patients with OCL discovered on US. According to the preset size groups, we found 30 (65.2%) small cysts, 11 (23.9%) medium cysts, and 5 (10.9%) large cysts. Sonographic characteristics of OCL by size groups and related to ages, are given in Table 1. Most lesions were small (65.2%), right-sided (78%) and simple (87%). These results are consistent with the findings of Emeksiz et al. [9], while Millar et al. [27] found ovarian cysts larger than 20 mm, in only 0.9% in prepubertal girls.

Table 1
OCL IN PREMENARCHEAL GIRLS

	OCL/group		Right Ovary		Left Ovary		Both Ovaries		simple OCL		complex OCL		ages (years)	
	n	%	n	%	n	%	n	%	n	%	n	%	limits	average
total	46	100%	36	78%	6	13.0%	4	8.7%	40	87.0%	6	13.0%	2-15	10.20
10-29 mm	30	65.2%	22	73.3%	5	16.7%	3	10.0%	30	100%	0	0.0%	2-13	9,5
30-49 mm	11	23.9%	9	81.8%	1	9.9%	1	9.9%	10	90.9%	1	9.1%	10-12	11,1
≥ 50 mm	5	10.9%	5	100%	0	0.0%	0	0.0%	0	0.0%	5	100%	10-15	12,5

There are two peak periods when ovarian cysts larger than 10 mm can be considered as normal: up to one year old and around menarche [28]. Outside these periods, such findings should raise the suspicion of abnormal hormonal release and consequently, the levels of estradiol and gonadotropins should be evaluated in order to exclude precocious puberty [29]. Age-specific incidence OCL and their distribution with respect to cyst size are shown in Figure 1.

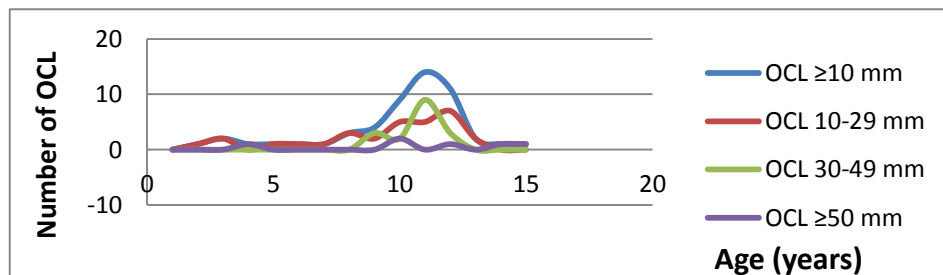


Fig. 1. Age-specific incidence OCL and their distribution with respect to the cyst size

In our study, peak ovarian incidence was at age 11 years (14; 27%); frequency was very low for patients aged 2-7 years, gradually increased up to 11 years, and then decreased in girls aged 13-15 years. The explanation may be the physiological quiescence of the prepubertal ovary, followed by a rise of its activity in the immediately premenarcheal period. The same frequency variations were also found by other authors, such as Tessitore et al [30] and Emeksiz et al [9]. We added 6 OCL discovered incidentally at the time of abdomino-pelvic surgery, 4 (67%) medium size and 2 (33%) large. In all cases, urgent surgery was performed, all were misdiagnosed as acute appendicitis (5; 83%) or ovarian torsion (1; 17%). Only in 4 cases (2 large cysts and 2 medium cysts) we operated the OCL, in the 2 other cases (medium size) we decided to follow them by ultrasound.

In premenarcheal girls, the most frequent complaints are abdominal pain and palpable abdominal mass [3]. Large OCL can present with compression signs as dysuria or constipation. When a cyst complication occurs, such as torsion or rupture, abdominal pain is severe and associated to vomiting [4]. In our study the most common symptom was abdominal pain (42 cases; 80%), followed by nausea (13; 25%). Rathore et al. found the incidence of abdominal pain to be 45.5% [4], but it was 85.7% in the study of Sonmez et al. [3]. Dysuria (5; 9%) and palpable tumor (5; 9%), occurred only in patients with large OCL. Associated vomiting (9; 17%) were present not only in the only case of ovarian torsion. The lack of specific symptoms makes difficult the diagnosis of OCL and its complications, and if we add the fact that the right side is more frequently affected [4], we can understand why this condition is usually misdiagnosed as acute appendicitis. More specific for this age group may be signs of precocious puberty, due to estrogen production from a functional cyst [10]. One patient of our study had vaginal bleeding, but hormone levels were normal, and the pediatric endocrinologist invalidated precocious puberty. Pediatric endocrinologist was asked to investigate 20 (38%) patients, because of acne (4), hirsutism (2), precocious puberty (2), autoimmune thyroiditis (1), elevated estradiol levels (4), obesity (8), and 5 menstrual

disorders after menarche occurs; excepting the case of tyroiditis, all blood analysis were found as normal. 14 patients (27%) experienced their first period during the study, and 7 of them (36%) presented dysmenorrhea or menstrual disorders. There was no relation between OCL and endocrinological conditions, but ovarian cysts in premenarheal girls may be predictive for future menstrual disorders.

Whenever an OCL is voluminous or complex, with solid component, the suspicion of malignancy is raised. In these particular cases, it may be necessary to perform a MRI and to request tumoral markers. MRI is noninvasive, has a great resolution for soft tissues and allows 3D reconstructions; but on the other hand, it is costly and often requires sedation [11]. Tumoral markers could be useful, being positive in 54–83% of malignant neoplasms. CA-125 has a relative specificity for epithelial malignancies, while α -fetoprotein (AFP) or β -human chorionic gonadotrophin (HCG) could suggest an immature teratoma or choriocarcinoma[12]. In our study we performed 5 MRI investigations (4 large and one medium OCL, all complex. Tumor markers were asked in 4 cases (2 large and 2 medium OCL, all complex), but were normal.

The main goal of OCL management in pediatric population is to preserve the ovaries. Generally, if the cystic lesion is asymptomatic and has simple aspect on US, it can be non-surgically managed, by US observation. Since in premenarheal girls OCL are usually of follicular origin, spontaneous resolution in 2 to 4 weeks is expected [9]. In a study series in premenarheal girls from Jordan, 89.2% of the ovarian cysts resolved spontaneously by 6 month [33]. Controversies about OCL size, torsion risk and the necessity of surgical intervention, still exist in the premenarheal age group. Some authors support the idea of conservatory treatment of simple OCL regardless the size, while others showed that OCL larger then 50 mm are more prone to torsion [9]. Millar et al. showed that US surveillance can be used in premenarheal girls with simple ovarian cysts smaller then 50 mm [27]. Surgery is indicated when OCL persist or increase in size, present symptoms, have US complex features (more then a few internal echoes that could be signs of internal hemorrhage), or are hormonally active. Ovary-sparing techniques are preferable, whenever it is possible, even in cases of torsion or mature teratomas[31]). Since fenestration and cyst puncture have been demonstrated to have a high rate of recurrence, it is preferably to perform either cystectomy, or the stripping technique [10]. Laparoscopic approach lately became the gold-standard in ovarian surgery in pediatric ages. Oophorectomy should be reserved only for malignant cases and some cases of ovarian torsion [32]. Unfortunately the rate of oophorectomies in pediatric ages is still high. A study from 2012 by Berger-Chen et al., showed a 40% rate of anexectomies for benign lesions [32]. In our study we treated conservative 44 patients (84.6%), and we operated 8 (15.4%).

The operated group had ages between 4.6 and 14.7 years (average 10.2 years), and OCL sizes were between 45 mm and 154 mm (average 77.2 mm). Related to OCL sizes, surgical treatment was used in 2 cases (2/11; 18%) of the medium OCL group, and in 6 cases of the large OCL group (6/7; 85.7%). We performed 7 cystectomies (87.5%) and one salpingo-oophorectomy (12.5%). Four (50%) of the surgical treated OCL were intraoperative discoveries, with one ovarian torsion (12.5%) misdiagnosed as acute appendicitis. In 7 cases (87.5%) ovaries had normal aspect on US, 6 month and 1 year after surgery. Histopathological findings were: 3 serous cystadenomas (37.5%), 3 simple serous cysts (37.5%), and 2 mature teratomas (25%). 75% were epithelial benign neoplasms, and 25% were germ-cells benign neoplasms. We performed only one salpingo-oophorectomy, in a case misdiagnosed as right renal cystic dysplasia; the right ovary was ectopic in the lumbar region, with unicornuate left uterus. Abbas et al [34] found 39.8% functional cysts, 26% mature teratomas and 5.6% serous cyst adenomas, but it wasn't a study on group ages.

In the conservative management group there were 44 patients; ages were between 2 and 15 years (average 10 years), OCL sizes were small (30; 68%), medium (13; 29.5%) and large (1; 2.5%), 40 (91%) cysts had simple appearance on US, and 4 (9%) were complex. 5 (50%) were small OCL and 5 (50%) were medium OCL. We used in 9 cases (20.5%) non-steroidal antiinflammatory drugs, in 14 cases (32%) associated with antibiotics; for the other 21 (48%) careful clinical and US survey were sufficient. Since abdominal pain disappeared in 10 cases after appendectomy, and in 21 cases with any kind of drug (total 31; 59.6%), we can conclude that OCL weren't the cause of pain. None of the girls had hormonal treatment. Of this group, 15 patients (34%) didn't return for control, but OCL sizes were between 11 mm and 27 mm, and US aspect was of simple cyst. Comparative data between conservative and surgical treatment are presented in Table 2.

Table 2
COMPARATIVE DATA BETWEEN CONSERVATIVE AND SURGICAL MANAGEMENT

	Surgical treatment	Conservative treatment
Number (n; %)	8; 15.4	44; 84.6
Median age (years)	10.2	10
OCL size in mm (interval; average)	45-154; 77.2	11-53; 25.5
Complex US appearance (n; %)	4; 50	4; 50

RMI (n)	2	3
Tumoral markers (n)	1	3
Hormonal treatment	0	0

Conclusions

Stratifying patients in premenarcheal and postmenarcheal groups seems to be more adequate from the physiological point of view, considering the permanent chemical and biochemical of sexual and pituitary hormones. Although the main symptom is abdominal pain, it doesn't seem to be related to OCL under 50 mm diameter. Most premenarcheal girls with OCL can be managed by US surveillance, even in some cases of large or complex lesions. If needed, the surgical treatment must aim to preserve ovarian tissue. Even though active hormonal OCL are rare, collaboration with the pediatric endocrinologist is of great help.

The increasing frequency of OCL in premenarcheal girls should determine pediatric practitioners of all medical specialties, to consider this condition in the diagnosis of abdominal pain. The multidisciplinary approach is beneficial for both treatment and follow-up.

References

- GUPTA, B., GULERIA, K., SUNEJA, A., VAID, N.B., RAJARAM, S., WADHWA, N., J Obstet Gynaecol., **36**, no. 4, 2016, p.515-517.
- ZOLTON, J.R., MASEELALL, P.B., Open J Obstet Gynecol., **3**, 2013, p. 12-16.
- SONMEZ, K., TURKYILMAZ, Z., KARABULUT, R., CAN BASAKLAR, A., Arch Argent Pediatr, **116**, 2018, p. 359-364.
- RATHORE, R., SHARMA, S., ARORA, D., Open Access Maced J Med Sci, **4**, no 4, 2016, p. 551-555.
- MUKHOPADHYAY, M., SHUKLA, R.M., MUKHOPADHYAY, B., MANDAL, K.C., RAY, A., SISODYIA, N., PATRA, M.P., J Indian Assoc Pediatr Surg, **18**, no 1, 2013, p. 16-19.
- BROOKFIELD, K.F., CHEUNG, M.C., KONIARIS, L.G., et al, J Surg Res, **156**, 2009, p. 45-49
- COHEN, H.L., SHAPIRO, M.A., MANDEL, F.S., SHAPIRO, M.L., AJR Am J Roentgenol, **160**, 1993, p. 583- 586
- BACK, S.L., MAYA, C.L., ZEWDNEH, D., EPELMAN, M., Pediatr Radiol, **47**, 2017, p. 1134- 1143.
- EMEKSIZ, H.C., DERINÖZ, O., AKKOYUN, E.B., PINARLI, F.G., BIDECE, A., J Clin Res PediatrEndocrinol, **9**, no. 1, 2017, p. 58-62.
- KELLEHER, C.M., GOLDSTEIN, A.M., Clin Obst and Gynecol, **58**, no. 1, 2015, p. 76-92.
- BRATU, A.M., RAICA, V.P., SALCIANU, I.A., ZAHARIA, C., POPA, V.B., LUPU, A.R., STEFANESCU, V., et al., Roumanian J Morph Embr, **58**, no. 4, 2017, p. 1212-1228
- LALA, S.V., STRUBEL, N., Pediatric Radiology, **49**, 2019, p. 1463-1475.
- AYDIN, B.K., SAKA, N., BAS, F., YILMAZ, Y., HALILOGLU, B., GURAN, T., TURAN, S., J Pediatr Adolesc Gynecol, **30**, no. 4, 2017, p. 449-455.
- RITCHIE, J., O'MAHONY, F., GARDEN, A., Ovarian Cyst Guideline, 2017
- SANNA, E., LOUKOGEORGAKIS, S., PRIOR, T., DERWIG, I., PARAMASIVAM, G., CHOUDHRY, M., LEES, C., J Perinat Med, **47**, no. 4, 2019, p. 418-421.
- MILLER, D., BLAKE, J.M., STRINGER, D.A., Obstet Gynecol, **81**, 1993, p. 434-438.
- FLORESCU L., MATEI, M.C., RUGINA, A., MINDRU, D.E., ANTIGHIN, S.P., MASTALERU, A., TEMNEANU, O.R., Z-score: an indicator of protein-calorie malnutrition. Rev Med Chir Soc Med Nat Iasi, 2017, 121(3): 493-498.
- MINDRU, D.E., MATEI, M.C., RUGINA, A., CIOMAGA, I.M., NISTOR, N., FLORESCU, L., The informed consent in pediatrics - a child's right. Rev Med Chir Soc Med Nat Iasi, 2019, 123(1): 153-160.
- FLORESCU, L., TEMNEANU, O.R., MINDRU, D.E., Social and Medical Implications of Teenage Motherhood. Revista de cercetari si interventii sociale 2016, 52: 80-91.
- PEACOCK, A., ALVI, N.S., MUSHTAQ, T., Arch Dis Child, **97**, 2012, p. 554-560.
- BUSILA, C., STUPARU, M.C., NECHITA, A., GRIGORE, C.A., BALAN, G., Good Glycemic Control for a Low Cardiovascular Risk in Children Suffering from Diabetes. Rev. Chim., **68**, no.2, 2017, p. 358
- ISOPESCU, F., AL MOMANI, R., Revista Medicala Romana, **58**, no.2, 2011, p. 88-91.
- LEVINE, D., BROWN, D.L., ANDREOTTI, R.F., et al., Radiology, **256**, no. 3, 2010, p. 943- 954
- KING, L.R., SIEGEL, M.J., SOLOMON, A.L., J Ultrasound Med, **12**, 1993, p. 577.
- KANIZSAI, B., ORLEY, J., SZIGETVARI, I., DOSZPOD, J., J Pediatr Adolesc Gynecol, **11**, no. 2, 1998, p. 85-88.
- BERGERON, L.M., BISHOP, K.C., HOEFGEN, H.R., ABRAHAM, M.S., TUTLAM, N.T., MERITT, D.F., PEIPERT, J.F., J Pediatr Adolesc Gynecol, **30**, no.1, 2017, p. 123-127.
- MILLAR, D.M., BLAKE, J.M., STRINGER, D.A., HARA, H., BABIAK, C., Obstet Gynecol, **81**, 1993, p. 434-438
- GILLIGAN, L.A., TROUT, A.T., SCHUSTER, J.G., SCHWARTZ, B.I., BREECH, L.L., ZHANG, B., TOWBIN, A.J., Pediatr Radiol, **49**, no. 8, 2019, p. 1042-1050.
- CAPRIO, M.G., DI SERAFINO, M., DE FEO, A., GUERRIERO, E., PERILLO, T., BARBUTO, L., VEZZALI, N., ROSSI, E., FERRO, F., VALLONE, G., ORAZI, C., J Ultrasound, **22**, no. 3, 2019, p. 273-289.

30. TESSIATORE, P., GUANA, R., MUSSA, A., LONATI, L., SBERVEGLIERI, M., FERRERO, L., CANAVESE, F., *MJ Pediatr Endocrinol Metab*, **25**, no. 5-6, 2012, p. 427-33.
31. WARNER, B., KUHN, J., BARR, L., *Surgery*, 1992, p. 112:749
32. BERGER-CHEN, S., HERZOG, T., LEWIN, S., BURKE, W.M., NEUGUT, A.I., HERSHMAN, D.L., WRIGHT, J.D., *Obstet Gynecol*, 2012, p. 119:270
33. ABBAS, P.I., DIETRICH, J.E., FRANCIS, J.A., BRANDT, M.L., CASS, D.L., LOPEZ, M.E., *J Pediatr Adolesc Gynecol*, **29**, no. 5, 2016, p. 506-510.

Manuscript received: 14.01.2020